



12512304121004680472

## तहसीलदार कार्यालय

क्रमांक : ४२०८१४४७१६६  
जिल्हा : अहमदनगर

### १ वर्षासाठी उत्पन्नाचे प्रमाणपत्र

प्रमाणित करण्यात येते की, श्री. अनिल महादेव सानप राहणार एकनाथवाडी गाव एकनाथवाडी, तहसील पाथर्डी, जिल्हा अहमदनगर येथील अर्जदार आहेत. त्यांचे प्रतिज्ञापत्र या आधारावर अर्जदार व त्यांच्या कुटुंबातील सर्व सदस्यांचे सर्व मार्गाने व साधनाने मिळालेले १ वर्षाचे उत्पन्न खालील प्रमाणे आहे.

वर्ष	वार्षिक उत्पन्न (₹)	अक्षरी (रुपये)
२०२२ - २०२३	३०,०००	तीस हजार

सदरचा दाखला श्री. अनिल महादेव सानप यांना मुलांच्या शिक्षणासाठी या कामासाठीच देण्यात येत आहे, तसेच त्यांनी कार्यालयास सादर केलेल्या कागदपत्रांच्या आधारे देण्यात येत आहे.

हे प्रमाणपत्र ३१ मार्च २०२४ पर्यंतच वैध राहील.

सादर केलेल्या दस्तऐवज / पुराव्याचे तपशील

१. शिधापत्रिकेची प्रमाणित प्रत
२. आधार कार्ड
३. स्वघोषण पत्र

स्थळ : पाथर्डी  
दिनांक : १३/०४/२०२३

Signature valid  
Digitally Signed by  
SHAYAM NADKAR  
तह Date: 2023-04-17 11:08:09 AM  
पाथर्डी

Printed By - OMTID : VLE Name : Balasaheb Nabaji Kasabe, Date: 13/04/2023 6:14PM

माहिती तंत्रज्ञान (मातृ) अधिनियम, २००० नुसार डिजिटल स्वाक्षरी असणारा हा दस्तऐवज कायदेशीररित्या वैध आहे.

पडताळणीसाठी - <https://www.mahaonline.gov.in/Verify> येथे मेट द्या किंवा बीएसएनएल, एमटीएनएल, टाटा मोबाईल क्र. वरून १६६/ अन्य क्र. वरून ५९९६९ या क्रमांकावर "MH<space>CSC<space>VFY<space><२० अंकी बारकोड क्रमांक>" असा एसएमएस पाठवा.



भारत सरकार  
GOVERNMENT OF INDIA



शशांक अनिल मानप  
Shashank Anil Sanap  
जन्म तारीख/ DOB: 19/08/2009  
पुरुष / MALE



8094 4533 5441

आधार-सामान्य माणसाचा अधिकार



भारतीय विशिष्ट पहचान प्राधिकरण  
UNIQUE IDENTIFICATION AUTHORITY OF INDIA

पत्ता:

मु एकनाथवाडी पो मुंगुसवाडे  
ता पाथर्डी जि अहमदनगर,  
एकनाथवाडी, अहमदनगर,  
महाराष्ट्र - 414113

Address:

mu Eknathwadi po Munguswade la  
Pathardi Dist Ahmadnagar,  
Ekanathwadi, Ahmadnagar,  
Maharashtra - 414113

8094 4533 5441

Aadhaar-Aam Admi ka Adhikar







## BILL ESTIMATE



**Patient Name :** Master SHASHANK ANIL SANAP(1010822) **Estimate Date :** 27/07/2023 13:24  
**Age :** 14Y **Gender :** Male  
**Schedule :** CASH **Consultant Name :** Dr. RAHUL CHAUDHARI  
**Visit No :** **Visit Date :**  
**Provisional Diagnosis :** **Line of Treatment :** Surgical  
**Estimate/Approx. Stay :** Non ICU 6 days, ICU 1 days **Expected Adm. :**  
**Preferred Bed Category :** General

Department	Surgery	Category
Spine Surgery	DEFORMITY SURGERY	Lev-07
Spine Surgery	MULTI LEVEL DECOMPRESSION	Lev-05
Spine Surgery	SPINAL FUSION-TLIF,PLIF	Lev-06

### Current Bill Value :

Services & Packages	General
Room/Bed Charges	20560
IP VISIT INTENSIVIST CHARGES	660
Surgery Charges	240800
IP Consultant Charges	12240
OT Charges	63300
Investigations Charges	60000
Miscellaneous Charges	880
Admin Charges	19540
Equipment Charges	50000
Implants Charges	370000
<b>Service Total</b>	<b>837980</b>
<b>Stores</b>	
IP Pharmacy	50000
OT Pharmacy	80000
<b>Item Total</b>	<b>130000</b>
<b>Grand Total</b>	<b>967980</b>



**Remarks : THIS IS PRIMARY ESTIMATE WITHOUT ANY COMPLICATION - IMPLANT COST APPROX -370000 /- AS CONFIRMED WITH DR RAHUL CHOUDHARI - SUBJECT TO CHANGE**

Patient has to pay 100% amount advance of treatment. Actual billing will differ based on the patient condition and surgical duration.  
 Consumables and pharmacy will vary according to the patient requirement and billed at actual. Extra stay will increase the bill.  
 "With reference to section 269 ST inserted by Finance Act 2017 under Income Tax Act we are unable to take cash of Rs.200000/- or more so please pay the amount by DD or by CARDS (CREDIT / DEBIT)"  
 THIS ESTIMATE NOT VALID FOR PCMC AND PMC BENEFIT HOLDER. THIS IS A PRIMARY ESTIMATE AND NOT FINAL BILL HENCE MAY VARY AS PER ACTUAL CONDITIONS ON TABLE AND IMPLANTS USES.

\*Emergency charges apply as per hospital policy on OPD holidays and after 8 pm to 8 am.

Category	General	Children Special Ward	Semi PVT AC	PVT AC	Luxury	Super Delux	Rose Wood	Daycare	Male General Ward (S)
Charges/Day	2200	2200	3500	6000	6500	8000	13800	6130	2200

*Varekha*  
**Civil Surgeon, Pune**

Entered By : dr13548

Printed Date/Time : 27/07/2023 13:24

Page 1 of 3

*- Jehangir Hospital is not- entered under*



## BILL ESTIMATE



Patient Name	: Master SHASHANK ANIL SANAP(1010822)	Estimate Date	: 27/07/2023 13:24
Age	: 14Y	Gender	: Male
Schedule	: CASH	Consultant Name	: Dr. RAHUL CHAUDHARI
Visit No	:	Visit Date	:
Provisional Diagnosis	:	Line of Treatment	: Surgical
Estimate/Approx. Stay	: Non ICU 6 days, ICU 1 days	Expected Adm.	:
Preferred Bed Category	: General		

\* Insurance company does not pay for certain billing expenses like administrative charge, admission charge, cashless processing fee, gloves, masks, other. which has to be paid in cash by patient.

\* In case of upgradation of room category, if opted for by the patient/relative, all charges will increase as per prevailing tariff of selected higher room category from the day of admission.

### Disclaimer:

The estimate is valid for only 15 days and subject to prevalent hospital tariff. While we make every effort to ensure the accuracy of our price estimates, the costs associated with medical care and diagnostic testing can vary substantially, depending on each individual's medical needs and circumstances. We cannot determine in advance the exact total cost of a procedure, because we cannot anticipate all of the charges that may be incurred in the course of treatment. As a result, the final bill may be greater than or less than the estimate provided. Also if any life-saving drugs & Procedures / higher antibiotics / investigations / total parenteral nutrition/Radiology-Imaging are required then it will lead to additional cost. Expenses for blood & blood products CT/MRI, ICU, HDU, PICU, NICU, special instruments are extra at actuals. 100% estimated amount payment to be made in advance for getting financial clearance for the procedure/surgery.

Make above full payment in advance at time of admission to billing counter only & take receipt of same.

### Counseling person Name & Signature

DR LATA D GADGE-dr13548

Patient/Relative Name

Patient/Relative  
Signature

Relation with Patient

Date & Time

Anil Sanap

अनिल सनाप

FATHER

27/07/2023 13:24

### Please read the following instructions carefully

1. This is only an "Estimate" and not the "Final Bill" and may vary.
2. The estimated expenses may vary in the certain conditions. For example
  - Increase in Post-operative ICU/HDU/CCU/RR/NICU/PICU Hospital stay.
  - Change in Billing Type. (e.g. Government to cash, other.)
  - Change in Bed category (i.e. from General to Private / semi Private AC).
  - Change in surgery category. (from simple to advanced).
  - Surgery planned under Local Anaesthesia but done under General Anaesthesia.
  - Usage of special equipments and instruments.
  - Unexpected / New /Additional surgery.
  - New medicines, drugs, disposables, implants, additional investigations.
3. Relatives will not be allowed to retain the bed / room if the patient is shifted to ICU.

## 7 ORANGE HOSPITAL

Pawana Nagar Housing Society, Chinchwad, Pimpri-Chinchwad, Maharashtra 411033

Phone : 020-27355777, 020-67191721 Mobile: 7775868888 Website: www.7orangehospitals.com

Email : assistance@7orangehospitals.com, billing@7orangehospitals.com

UHID : PT16847  
PATIENT NAME : MAST SHASHANK ANIL SANAP  
ADDRESS : Traveninagar, Tower Line Road Pune

DATE : 13/07/2023 05:46 PM  
AGE/SEX : Male, 13 Yrs  
REF. BY : Private  
MOB.NO. : 9922544197

Dr. Rahul Chaudhari

CO RT Sided scoliosis  
severe chest bump + c.

Adv.

— Xs whole spine  
AP Lat

— Need Scoliosis..

CT-Scan - Dorsal Spine

MRI - whole spine screening

2D Echo / ECG

USG - Abd + Pelvis

**DR. RAHUL DNYANDEO CHAUDHARI**  
MS ORTHO, ECFMG (USA), FELLOWSHIP IN  
SPINE & SCOLIOSIS SURGERY (USA)  
2002/02/0807



## 7 ORANGE HOSPITAL

Pawana Nagar Housing Society, Chinchwad, Pimpri-Chinchwad, Maharashtra 411033  
Phone : 020-27355777, 020-67191721 Mobile: 7775868888 Website: www.7orangehospitals.com  
Email : assistance@7orangehospitals.com, billing@7orangehospitals.com

UHID : PT16847  
PATIENT NAME : MAST SHASHANK ANIL SANAP  
ADDRESS : Traveninagar, Tower Line Road Pune

DATE : 25/07/2023 06:43 PM  
AGE/SEX : Male, 13 Yrs  
REF. BY : Private  
MOB.NO. : 9922544197

S/B Dr. Rahul Chaudhari

ad. (RP) Therāci scoliosi.

D to D<sub>10</sub> Scoliosis.

— <sup>Adh</sup> Need scoliosis corset

Syp. Aphirate

10ml — 10ml

— Vitencial pro protein powder



DR. RAHUL DNYANDEO CHAUDHARI  
MS ORTHO, ECFMG (USA), FELLOWSHIP IN  
SPINE & SCOLIOSIS SURGERY (USA)  
2002/02/0807



पुणे महानगरपालिका व क्रस्ना डायग्नोस्टिक्स लि. (पूर्वीचे क्रस्ना डायग्नोस्टिक्स प्रा.लि.)

यांच्या संयुक्त उपक्रमाद्वारे सार्वजनिक खाजगी भागीदारी तत्वावर  
"डॉ. शामा प्रसाद मुखर्जी योजनेअंतर्गत" डायग्नोस्टिक्स सेवा



## **2D ECHOCARDIOGRAPHY & COLOR DOPPLER STUDY**

**NAME:** SHASHANK SANAP **AGE/SEX:** 13 YEARS/MALE **DATE:** 18/07/2023

### **FINDINGS:**

Poor echo windows.

Left atrial size is normal.

Left ventricle is normal sized, no wall motion abnormality, LVEF - 60%, no diastolic dysfunction.

Right atrial and ventricular size is normal, right ventricular function is normal.

Mitral valve has normal structure, no stenosis, no regurgitation.

Aortic valve is thin, trileaflet, no stenosis, no regurgitation, systolic PG is 2 mmHg.

Tricuspid valve is normal, trivial regurgitation present, RVSP by TR jet is 18 mmHg.

Pulmonary valve is normal.

Septae (IAS/IVS) appears intact on Trans-Thoracic study.

No clot or vegetation seen. No pericardial effusion.


Aorta and pulmonary artery are normal in size.

IVC size is normal and >50% collapses with inspiration.

### **CONCLUSION:**

**NORMAL CARDIAC CHAMBER DIMENSIONS**  
**NORMAL LV SYSTOLIC FUNCTION, LVEF 60%**  
**NO DIASTOLIC DYSFUNCTION**  
**NO PULMONARY HYPERTENSION**

Note: This Echocardiography study is performed on Wipro GE Logic F8 Machine. Please correlate clinically.

  
**DR. JIGNESH PARIKH**  
**DNB (MED), DNB (CARD)**  
**CARDIOLOGIST**





पुणे महानगरपालिका व कर्स्ना डायग्नोस्टिक्स लि. (पूदीचे कर्स्ना डायग्नोस्टिक्स प्रा.लि.)

यांच्या संयुक्त उपक्रमाद्वारे सार्वजनिक खाजगी भागीदारी तत्वावर  
"डॉ. शामा प्रसाद मुखर्जी योजनेअंतर्गत" डायग्नोस्टिक्स सेवा



PATIENT NAME: MR SHASHANK SANAP  
REF DR: DR. RAHUL CHAUDHARY  
AGE/SEX: 13 YRS/MALE  
DATE: 15/07/2023

#### SONOGRAPHY OF ABDOMEN AND PELVIS

The **liver** appears normal in size, shape (measures 12.4 cm) and shows normal echotexture. No focal lesion is seen. The hepatic venous radicals and intrahepatic biliary tree appear normal. The portal vein and CBD appears normal.

The **gall bladder** is partially distended with a normal wall thickness and there are no calculi seen in it. No wall edema / pericholecystic collection seen.

The **pancreas & spleen** appear normal in size and echotexture. No focal lesion seen.

The **right kidney** measures 7.7 x 3.2 cms and the **left kidney** measures 7.5 x 3.4 cms. Both kidneys appear normal in size, shape & echotexture. There is no hydronephrosis / hydroureter or calculus seen on either side.  
**Mild dilatation of left pelvicalyceal system.**


The **urinary bladder** distends well and is normal in shape and contour. No intrinsic lesion or calculus is seen in it. The bladder wall is of normal thickness.

The **prostate** is normal for age.

There is no ascites or lymphadenopathy seen.  
The aorta and IVC appear normal.  
Visualized bowels appears normal.

#### IMPRESSION:

- Mild dilatation of left pelvicalyceal system.
- No other significant abnormality is seen.

  
DR AVULA ANANTHESWAR KUMAR  
MBBS, MD (RADIO-DAGNOSIS)  
REG NO. 2022/08/6631

(Please bring all old test reports for follow up study). Investigation have there limitations. Solitary pathological/radiological and other investigations never confirm the final diagnosis. They only help in diagnosis in correlation to clinical symptoms and other related tests. Please interpret accordingly



पुणे महानगरपालिका व कर्स्ना डायग्नोस्टिक्स लि. (पूढीचे कर्स्ना डायग्नोस्टिक्स प्रा.लि.)  
यांच्या संयुक्त उपक्रमाद्वारे सार्वजनिक खाजगी भागीदारी तत्वावर  
“डॉ. शरमा प्रसाद मुखर्जी योजनेअंतर्गत” डायग्नोस्टिक्स सेवा



Patient ID: JNHP 23070061537	Patient Name: MAST SHASHANK SANAP
Age: 13 Years	Sex: M
Accession Number: 1234	Modality: CT
Referring Physician: DR RAHUL CHAUDHARI	Study: CT DORSAL SPINE PLAIN
Study Date: 15-Jul-2023	

**CT SCAN OF DORSAL SPINE (PLAIN)**

**Protocol:**

Plain CT scan of dorsal spine has been done.

**Clinical Brief:**

History of scoliosis since birth. Complaints of difficulty in walking and seating.

**Observations:**

Severe scoliosis of dorsal spine is noted with convexity towards right, Cobb's angle is approx. 30 Degrees.

Vertebral bodies and their posterior neural arches otherwise appear intact.

No fracture / erosion / destruction noted.

No significant CT scan demonstrable disc prolapse is noted.

Bony spinal canal appears normal. No bony canal stenosis is noted.

Paravertebral soft tissues appear normal.

**IMPRESSION :**

Severe scoliosis of dorsal spine is noted with convexity towards right, Cobb's angle is approx. 30 Degrees.

Investigations have their limitations. Solitary pathological/Radiological and other investigations never confirm the final diagnosis. They only help in diagnosing the disease in correlation to clinical symptoms and other related tests. Please interpret accordingly.

*Eshan Thotwe*

Dr. Eshan Thotwe  
M.B.B.S., M.D.(Radiology)  
Reg.No. 2009/03/0850

Date: 15-Jul-2023 20:14:38

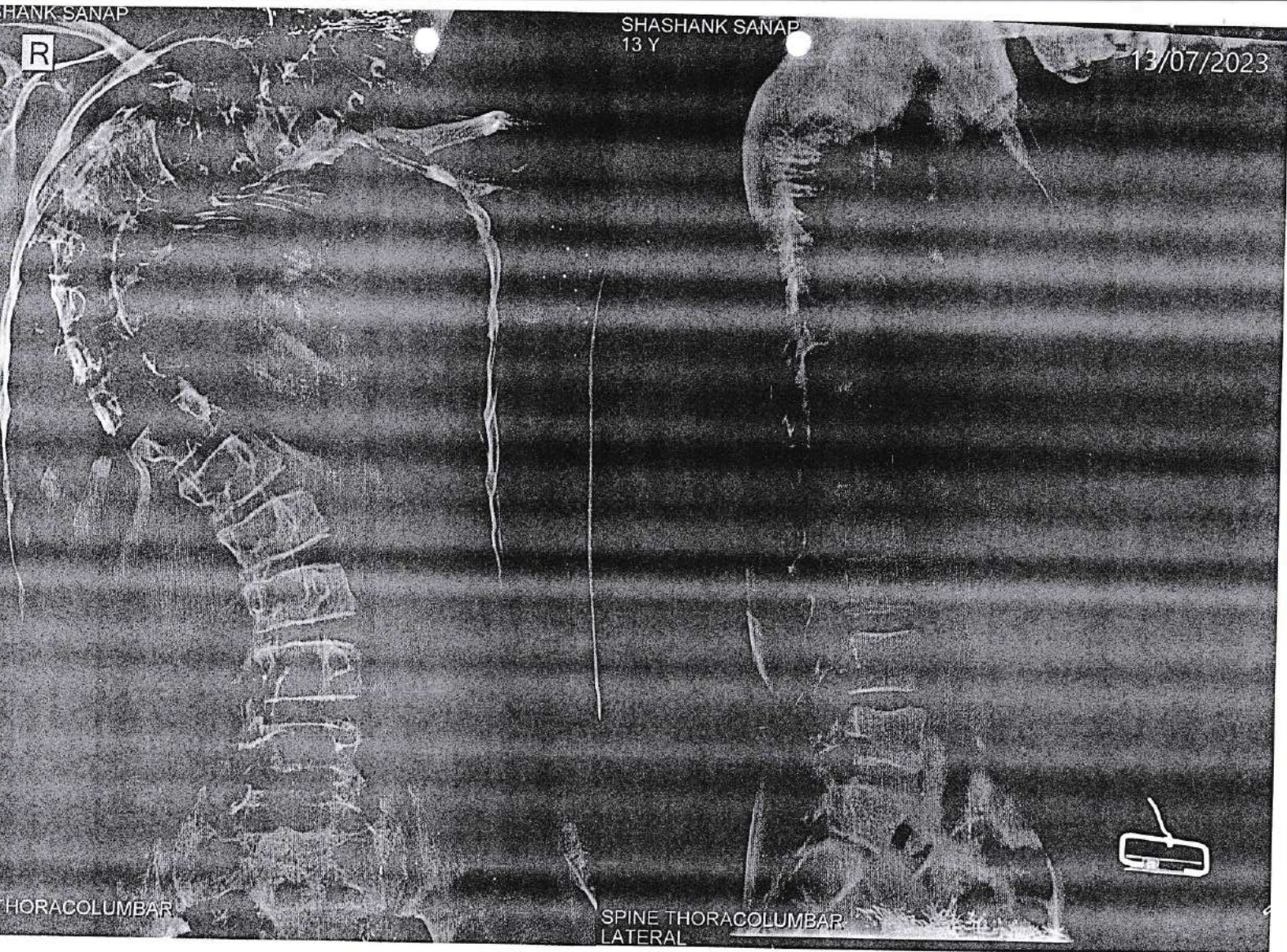


SHASHANK SANAP

R

SHASHANK SANAP  
13 Y

13/07/2023



THORACOLUMBAR

SPINE THORACOLUMBAR  
LATERAL

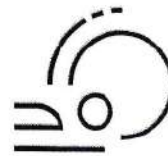






Ruby Ailcare™  
Services Pvt. Ltd.  
CIN: U85110PN2005PTC020949

DIAGNOSTIC IMAGING SERVICE



3.0  
TESLA  
MRI



Pimpri-Chinchwad Municipal Corporation & Ruby Ail Care Services Joint Venture (Cardiac Centre, MRI Centre & CT Scan Centre)

PATIENT NAME	MASTER SHASHANK SANAP	AGE / SEX	: 014Y / Male
PATIENT ID	: 210359	DATE	: 25-Jul-2023

### MRI WHOLE SPINE SCREENING

There is dextroscoliotic deformity of the spine. This is seen centering around D7-8 vertebra.  
There is possibility of atlanto occipital assimilation.

Possibility of sagittal cleft vertebra is seen at D6, D7, D8, D9.

#### Screening MR of the cervical spine:

The vertebral body heights are normal. No evidence of modic change or marrow edema.  
There is no evidence of lysis or listhesis.  
Normal disc hydration is maintained.  
No disc bulge is seen.  
No central canal or neuroforaminal stenosis. The cervical cord is normal in signal intensity.  
The ligamentum flavum and facet joints are normal.

#### Screening MR of the thoracic spine:

The vertebral body heights are normal. No evidence of modic change or marrow edema.  
There is no evidence of lysis or listhesis. The discs are normal in signal intensity.  
No central canal or neuroforaminal stenosis.  
The thoracic cord is normal in signal intensity.  
The ligamentum flavum and facet joints are normal.

#### Screening MR of the lumbar spine:

The vertebral body heights are normal. No evidence of modic change or marrow edema.  
There is no evidence of lysis or listhesis. The discs are normal in signal intensity.  
No central canal or neuroforaminal stenosis.  
The ligamentum flavum and facet joints are normal.  
Note is made of a cystic lesion in the left lateral aspect of neck measuring 2 x 1.5 cm.

#### IMPRESSION:

Dextroscoliotic deformity of the spine center in around D7-D8 vertebrae.  
Possibility of atlanto occipital assimilation.  
There is possibility of sagittal cleft vertebra at D6, D7, D8 and D9.  
Advice CT correlation/detailed evaluation.

*K. Asthana*

Dr Karan Asthana  
Consultant Radiologist  
MBBS, M.D., Musculoskeletal Fellowship (DWH)  
Regn No: 2022/10/8655

PIMPRI

THERGAON

+91 90229 28574 020 6733 2317

+91 87930 93068 020 6833 7323/ 6833 7322

**Dr. Rahul Chaudhari**

Consultant Spine/Scoliosis Surgeon

M.S.(Orthopedics), ECFMG(USA)

Clinical Fellow - Adult Spine Surgery(USA)

Clinical Fellow - Pediatric Spine/Scoliosis Surgery(USA)



**SPINE** | HEALTH  
CLINIC  
Complete Spine Care

Consultant Spine Surgeon | Jehangir | Hardikar | 7 Orange | KEM | Columbia Asia

18/9/23

To,

Jehangir Hospital

This patient - Shashank Anil Sanap M/15yr  
w/ Dorsal scoliosis. He needs scoliosis  
correction. Patient is poor and  
not able to pay the expenses.

I am willing to do this surgery in  
charity with minimal cost.



